CHAPTER

39 The hip

Learning objectives

To understand:

- The anatomy and biomechanics of the hip and their clinical implications
- The clinical presentation, aetiology and management of common hip pathologies
- The principles of joint replacement including important complications
- The advances in surgical practice in this field

ANATOMY AND BIOMECHANICS

Applied anatomy

The hip is a ball-and-socket joint formed by the head of the femur and the cup-shaped acetabulum (Latin: 'little vinegar cup') (*Figure 39.1*). The joint allows a considerable range of movement in different planes and is still inherently stable because of its bony anatomy and the static and dynamic stabilisers. The static stabilisers are composed of the iliofemoral and pubofemoral ligaments anteriorly and the ischiofemoral ligament posteriorly; together with the joint capsule and the labrum (*Figure 39.1*). The muscles running across the joint (short external rotator muscles and gluteus maximus posteriorly, the iliopsoas anteriorly and the hip abductors laterally) constitute the dynamic stabilisers. The acetabular labrum is a fibrocartilaginous structure that is triangular in cross-section and attaches to the rim of the acetabulum, except at its base, where it is replaced by a ligament called the transverse acetabular ligament. The labrum helps in deepening the socket, thereby enhancing stability. It also acts as a fluid seal and thereby helps to improve joint lubrication. The femoral head derives its blood supply mainly from the retinacular branches of the medial circumflex femoral artery and has a small contribution from the artery of the ligamentum teres.

Summary box 39.1

Anatomy

- The hip joint is a ball-and-socket joint, with both static and dynamic stabilisers
- Static stabilisers include the capsule, ligaments and labrum
- Dynamic stabilisers consist of the muscles acting across the joint
- Blood supply to the femoral head is mainly derived from the medial circumflex femoral artery

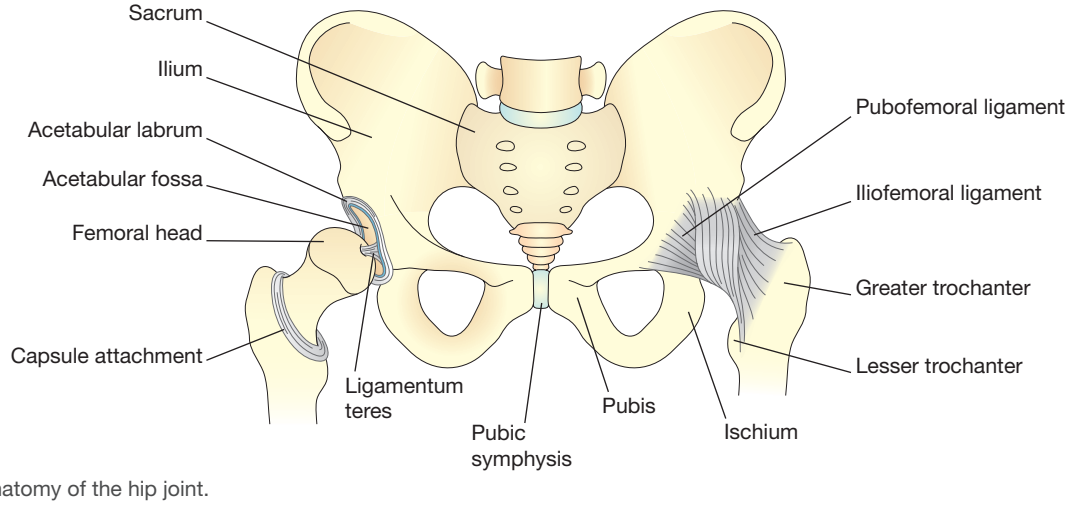

Figure 39.1 Anatomy of the hip joint.

Biomechanics of the hip joint

Kinetic analysis reveals that forces as high as three times body weight can be exerted across the hip joint during activities of daily living, and eight times body weight during physically demanding activities. This is primarily the result of contraction of muscles crossing the hip joint. The abductors, because of their insertion at the greater trochanter, help in supporting the pelvis when the patient stands on the ipsilateral leg and thereby form the basis of the Trendelenburg test (*Figure 39.2*).

Summary box 39.2

Forces going through the hip joint

- Lifting leg from bed – one and a half times body weight
- Standing on one leg – three times body weight
- Running and jumping - ten times body weight

CONDITIONS AFFECTING THE HIP

Common hip pathologies in the paediatric age group and secondary to trauma are covered in *Chapters 29, 32 and 44*. This chapter focuses on the acquired pathological conditions in the adult.

Avascular necrosis

Avascular necrosis (AVN), or osteonecrosis of the femoral head, occurs because of an interruption in the blood supply to the femoral head, leading to bone death. This results in collapse of the femoral head initially, and eventually secondary osteoarthritis (OA). AVN can be primary (idiopathic) or secondary to other pathology (*Table 39.1*).

TABLE 39.1 Aetiology of avascular necrosis of the femoral head.

- Steroids
- Alcohol excess
- Idiopathic (see Perthes' disease; see *Chapter 44*)
- Sickle cell disease
- Haemoglobinopathies
- Caisson disease ('the bends' in divers)
- Hyperlipidaemia
- Systemic lupus erythematosus
- Gaucher's disease
- Chronic liver disease
- Antiphospholipid antibody syndrome
- Radiotherapy
- Chemotherapy
- Human immunodeficiency virus
- Hypercoagulable states (protein C and protein S deficiency)

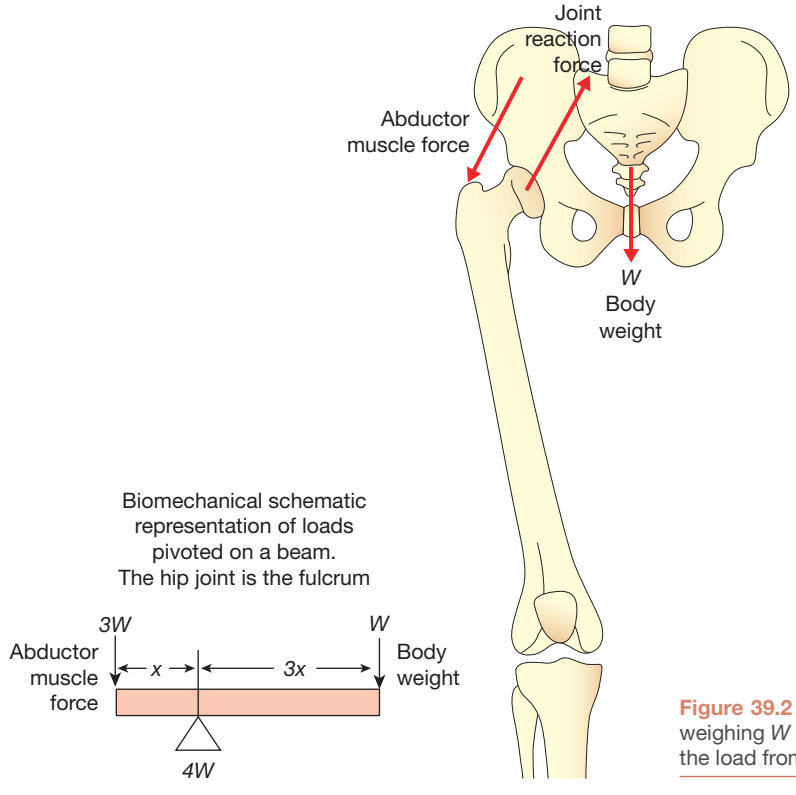

Figure 39.2 Load on the hip joint when a subject weighing *W* stands on one leg. Hopping increases the load from 4*W* to 10*W*.

Friedrich Trendelenburg, 1844–1924, Professor of Surgery successively at Rostock (1875–1882), Bonn (1882–1895) and Leipzig (1895–1911), Germany. The Trendelenburg position was first described in 1885.
A **caisson** is a watertight chamber used to protect construction workers during the building of underwater structures by means of pressurised air introduction.
Philippe Charles Ernest Gaucher, 1854–1918, physician, Hôpital St Louis, Paris, France, described familial splenic anaemia in 1882.
Georg Clemens Perthes, 1869–1927, Professor of Surgery, Tübingen, Germany, described osteochondritis of the femoral capital epiphysis in 1910.

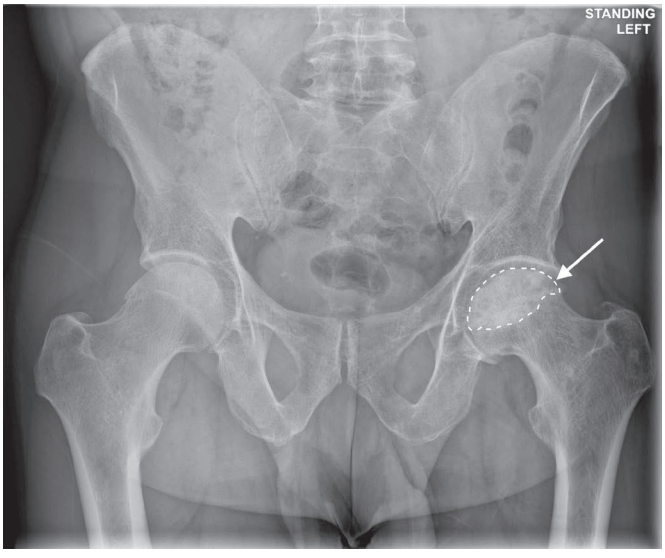

Figure 39.3 Radiological appearance of avascular necrosis of the femoral head of the left hip. There is evidence of femoral head sclerosis (dashed line and arrow) as a consequence of avascular necrosis.

Clinical features

AVN usually affects men aged 35–45 and is bilateral in over 50% of patients. The patient is frequently asymptomatic in the early stages. As the disease progresses the patient may complain of an ache in the groin and walk with a limp. Clinical examination in the early stages is usually normal but may reveal a positive Thomas's test and limitation in the range of movement as the disease progresses.

Investigations

A weight-bearing anteroposterior (AP) radiograph of the pelvis along with a lateral radiograph will show the classical features of AVN, including increased sclerosis in the early stages and the crescent sign indicating subchondral bone resorption. In the late stages there may be femoral head irregularity indicating the onset of arthritis (*Figure 39.3*), and flattening, indicating a segmental head collapse. However, radiographs may be normal in the early stages of the disease and, therefore, the most sensitive and specific way of investigating these patients is with magnetic resonance imaging (MRI). MRI allows accurate assessment of the extent of involvement of the femoral head and can also identify associated bone marrow changes. This helps in early diagnosis and the prediction of prognosis (*Figure 39.4*). In 1985, Ficat classified the disease into five stages. In 1995, Steinberg modified this classification into seven stages (0–VI) based upon both radiograph and MRI appearance (*Table 39.2*). Stages I–IV are further divided according to the extent of femoral head involvement (A; mild, B; moderate and C; severe).

Management

Conservative treatment in well-established cases usually leads to poorer outcomes and is therefore not recommended. The choice of surgical treatment depends upon whether the femoral head has collapsed or not. In the pre-collapse stage the principle is to preserve and preferably encourage revascularisation of the femoral head, whereas in the collapse stage the aim is to bring the undamaged parts of the femoral head into the load-bearing zone of the hip joint.

The surgical treatment for the pre-collapse stage includes core decompression, which is aimed at relieving the intravascular congestion in the femoral head and thereby pain. This can be achieved with or without bone grafting or combined with bone-marrow-derived cell therapies; a vascularised bone graft can also be used to stimulate bone formation and support the femoral head. Once the femoral head has collapsed, either a femoral osteotomy (which aims to transfer the weight-bearing area of the femoral head and thereby protect the collapsed segment) or a joint replacement (if degenerative changes have set in) is the preferred option (see *Primary total hip replacement*).

Figure 39.4 Magnetic resonance imaging scan of the hip joint showing avascular necrosis (arrows). (a) Coronal view; (b) sagittal view.

Hugh Owen Thomas, 1834–1891, general practitioner, Liverpool, UK. He is regarded as the founder of orthopaedic surgery although never holding a hospital appointment, preferring to treat patients in their own homes. He introduced the Thomas splint in 1875.
R Paul Ficat, 1917–1986, Professor of Clinical Orthopaedic Surgery and Traumatology, Université Paul Sabatier, Toulouse, France.
Marvin E Steinberg, contemporary, Professor of Orthopedic Surgery, Philadelphia, PA, USA.

TABLE 39.2 Steinberg's classification of avascular necrosis of the femoral head based on the type of radiological change on radiographs and magnetic resonance imaging (MRI).

Stage	Description
0	Normal or non-diagnostic radiograph, bone scan or MRI
I	Normal radiograph, abnormal MRI or bone scan
II	Sclerosis and cysts
III	Subchondral collapse, crescent sign
IV	Flattening of the head, normal acetabulum
V	Acetabular involvement
VI	Obliteration of joint space

Summary box 39.3

AVN of the femoral head

- Patients can be asymptomatic in the early stages and therefore a high index of suspicion is necessary for initial diagnosis
- MRI scan is required for early diagnosis
- Treatment is based on whether the patient presents before or after the femoral head has collapsed
- In the pre-collapse stage treatment focuses on revascularisation of the femoral head
- In the collapsed stage, the aim is to reorient the damaged area of the femoral head or replace the joint if degenerative changes have set in
- Prognosis is dependent upon the extent of femoral head involvement

Femoroacetabular impingement

Femoroacetabular impingement (FAI) has recently been recognised as a cause of hip pain in the young adult and may lead to secondary hip OA. Two distinct types of FAI have been described – cam and pincer – although many patients have a mixed picture with both morphologies occurring simultaneously. Cam FAI is secondary to abnormal morphology of the femoral head and neck junction whereas pincer FAI is a result of anterior overcoverage or retroversion of the acetabulum. The cam deformity is typically described as an abnormal bony bump at the femoral head–neck junction (*Figure 39.5a*), measured as an alpha angle of >55° (*Figure 39.5b,d*). The alpha angle is ideally measured on the Dunn view, which is a 45° lateral view of the hip. This view is useful to identify subtle cam deformities that are not clearly visible on the AP radiograph (*Figure 39.5c,d*, arrow pointing to the cam deformity). The alpha angle can be measured on the AP radiograph if severe but the extent is accurately assessed on the Dunn view. The alpha angle is the angle made by a line along the centre of the femoral neck to the centre of the femoral head and another from the centre of the femoral head to the point on the femoral head outside the imaginary circle, as shown in *Figure 39.5b,d*.

On the other hand, pincer deformity is defined by a lateral centre–edge angle (LCEA) measured on the AP radiograph (*Figure 39.5b*) of over 40° (normal 25–40°). The LCEA is the angle formed between an imaginary vertical line from the centre of the femoral head and another from the centre of the femoral head to the lateral edge of the acetabulum.

The impingement, which occurs during deep hip flexion or earlier with internal rotation as a result of the abnormal morphology, results in damage to the labrochondral junction. Patients typically present with groin pain and limitation of activities related to deep bending and rotation. Plain radiographs are useful in evaluating the bony deformity. Further evaluation with MRI typically reveals acetabular labral and chondral lesions and abnormal femoral head morphology in the case of cam deformity. Computed tomography (CT) scan, especially three-dimensional (3D) CT, is helpful in accurately assessing the proximal femoral morphology, acetabular coverage and posterior joint space and allows for planning management. Treatment options for FAI depend on the patient's symptoms and vary from non-operative treatment to hip preservation procedures that aim to address labral, chondral and bony pathology; this can be achieved with arthroscopy, safe surgical hip dislocation or osteotomy of the femur and/or acetabulum.

Hip dysplasia in young adults

Hip dysplasia is a condition in which there is under-coverage of the femoral head, secondary to a shallow acetabulum. Hip dysplasia is defined as an LCEA of <20° and/or an acetabular index of >10° (*Figure 39.6*). The acetabular index (also called the Tönnis angle) is the angle formed by an imaginary line through the superior weight-bearing portion of the acetabulum and an imaginary horizontal line (*Figure 39.6*).

Thorough screening and timely management of developmental dysplasia of the hip (DDH) as a child is aimed at preventing problems during early adulthood. In mild cases of DDH symptoms are not present until the person is a teenager or an adult. Abnormal biomechanics in hip dysplasia leads to progressive chondral damage and labral tears. Treatment options depend on the severity of dysplasia and the extent of damage in the hip joint, with options being hip arthroscopy, periacetabular osteotomy or total hip replacement (THR) in cases where there is evidence of arthritis.

Extra-articular hip pathology

Hip pain can also occur as a result of impingement of extra-articular structures resulting in restriction of activities. *Table 39.3* shows the common causes of extra-articular hip impingement. Snapping hip syndromes (shown in *Table 39.3*) can also present with hip pain. Imaging modalities such as ultrasound and MRI may aid the diagnosis. Treatment begins with non-operative measures such as physiotherapy with surgical procedures aimed at treating the primary pathology in refractory cases. See *Further reading* for additional information.

Denis M Dunn, 1916–2001, consultant orthopaedic surgeon at the Colchester and District Hospital Group and honorary assistant surgeon at The London Hospital, London, UK.
Dietrich Tönnis, 1927–2010, German paediatric orthopaedic surgeon. He had an interest in the hip joint, especially dysplastic hips.

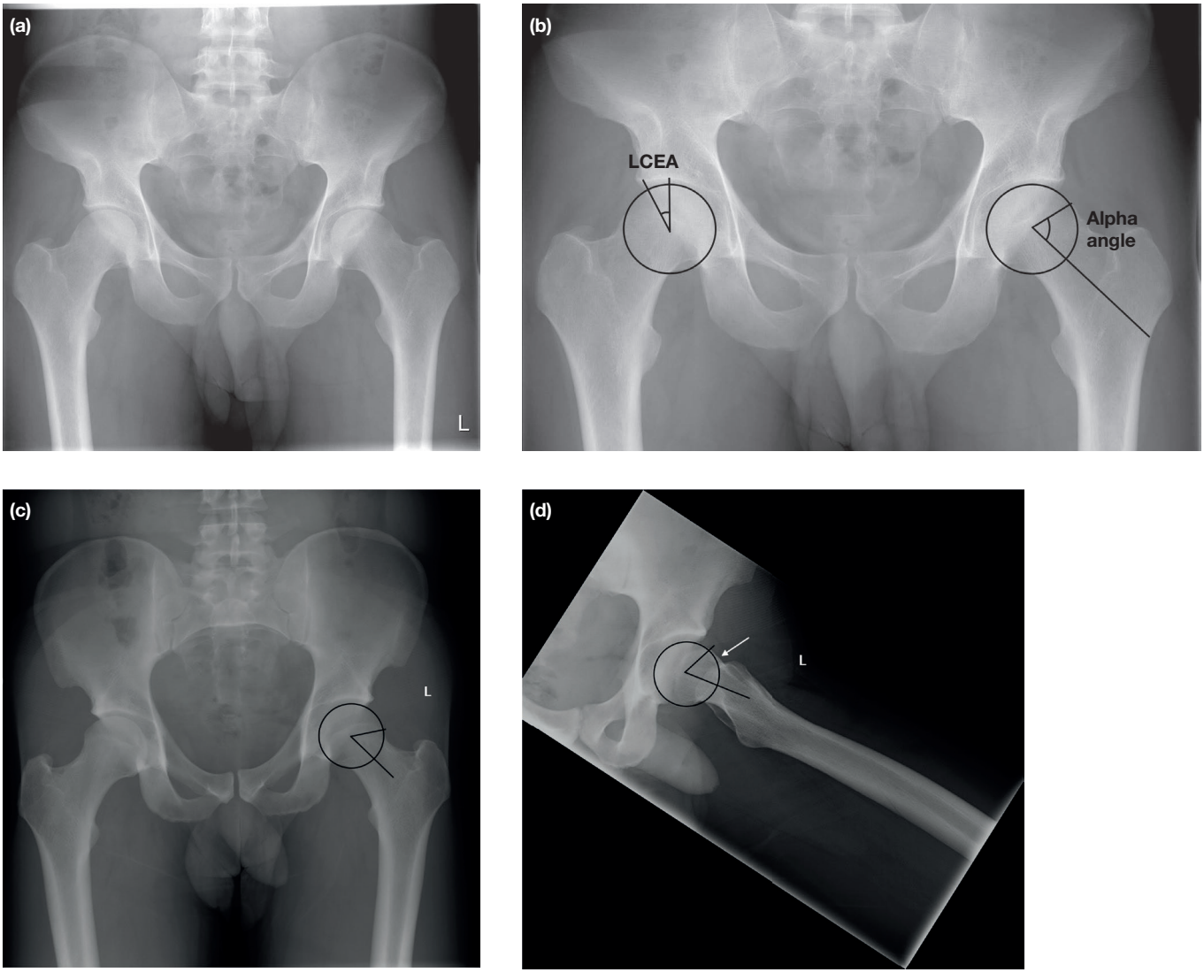

Figure 39.5 Radiograph showing cam femoroacetabular impingement (a), marked over the femoral head (b) with the arrow pointing to the cam deformity. (c) Anteroposterior radiograph and (d) a subtle cam lesion picked up on the lateral view. The alpha angle measurement is used to assess the severity of cam deformity (normal ≤55°). The lateral centre–edge angle (LCEA) is a measure of acetabular coverage (normal = 25–40°).

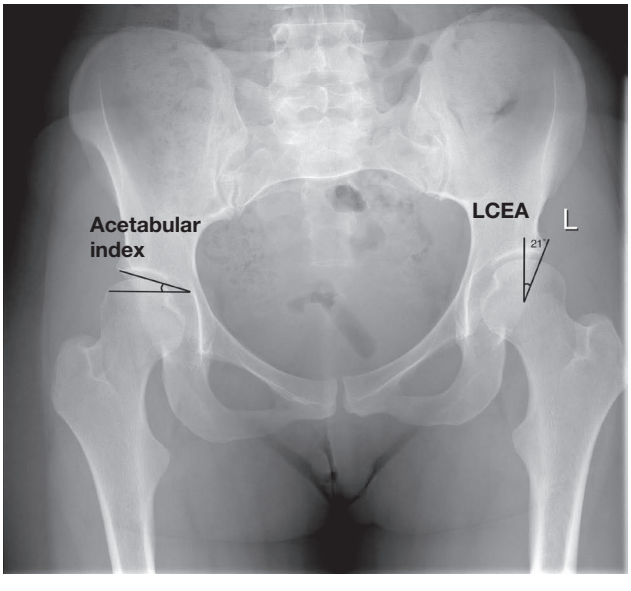

Figure 39.6 Plain radiograph showing bilateral hip dysplasia: uncovering of the femoral head as measured by a centre–edge angle (CEA) of less than 20°. Normal CEA is 25–40°. A CEA of 20–25° is categorised as borderline dysplasia of the hip. An acetabular index of >10° is suggestive of hip dysplasia.

TABLE 39.3 Extra-articular hip impingement and externally snapping hip syndromes.

Pathology	Description
Extra-articular hip impingement	
Iliopsoas impingement	Impingement between the iliopsoas muscle and the labrum, resulting in distinct anterior labral pathology
Subspine impingement	Impingement between an enlarged or malorientated anterior inferior iliac spine and the distal anterior femoral neck
Ischiofemoral impingement	Compression of the quadratus femoris muscle between the lesser trochanter and the ischial tuberosity
Deep gluteal syndrome	Entrapment of the sciatic nerve in the deep gluteal space resulting in pain in the buttock
Snapping hip syndromes	
Internal snapping hip syndrome	Iliopsoas tendon glides over the hip joint, producing a snapping sensation and eventually leading to labral tear
External snapping hip syndrome	Iliotibial band glides over the greater trochanter and snaps, producing an audible and/or visible snap

HIP PRESERVATION PROCEDURES

For the conditions above, in which degenerative change is not predominant, a variety of surgical procedures are now described with the aim of preserving the hip joint.

Diagnostic hip injection

Identification of the source of symptoms is essential to ensure appropriate management. Since the hip joint is deeply seated, several extra-articular pathologies can present with hip and groin pain and the diagnostic hip injection can help elucidate whether the pain is extra- or intra-articular in origin. This is performed as a day case procedure under image intensifier (portable x-ray machine) guidance under appropriate anaesthesia. Using aseptic precautions, a long spinal needle is inserted into the hip joint. The position of the needle is confirmed by injecting either a small amount of radio-opaque contrast dye or air to provide a contrast arthrogram. Once the intra-articular position is confirmed, a mixture of local anaesthetic and steroid is injected into the hip joint.

The procedure can also be therapeutic and is an essential tool that can help in prognosis as well prior to proceeding with hip preservation procedures (arthroscopy or osteotomy), especially in cases of uncertainty relating to the source of the pain and therefore the diagnosis.

Arthroscopy of the hip

The hip joint presents challenges to arthroscopy in terms of access and instrumentation of the deeply recessed femoral head in the acetabulum and the surrounding thick fibrocapsular and muscular envelope. Technical advances, including an improved ability to manage the capsule and gain exposure, have led to an expanding list of applications, including the treatment of symptomatic labral tears, FAI and the removal of loose bodies, e.g. synovial chondromatosis. Arthroscopy allows a clear view of the femoral and acetabular articular surfaces, the labrum, the ligamentum teres and the head–neck junction, along with the surrounding synovium and its folds, and the peritrochanteric space. Advantages include minimally invasive access to all these structures coupled with rapid recovery, in comparison with open surgery. However, there is a steep learning curve with hip arthroscopic procedures and adequate training of this procedure with a mentored independent practice in the early part of a surgeon's career is an essential part of achieving a successful outcome.

Osteotomies around the hip

The goal of an osteotomy around the hip is to redistribute forces evenly across the joint, thereby eliminating excessive point loading. This can be achieved by performing an osteotomy on the femoral or the acetabular side, depending upon the desired goal, e.g. an excessive valgus neck–shaft angle and an uncovered femoral head on the lateral aspect can be corrected by carrying out a varus femoral osteotomy. Similarly, a redirection osteotomy on the acetabular side can also be performed to improve coverage of the femoral head in cases of hip dysplasia. The common indications for an osteotomy around the hip in the adult age group are shown in *Table 39.4*. Ideally, an osteotomy should be considered in a young patient who maintains a good range of movement of the hip and whose imaging studies (radiographs and/or CT scan or MRI scan) show a joint devoid of significant degenerative change.

TABLE 39.4 Indications for osteotomy around the hip in the adult age group.

Femoral osteotomy	Periacetabular osteotomy (PAO)
Perthes' disease Osteoarthritis in a young patient Slipped capital femoral epiphysis Avascular necrosis	Developmental dysplasia of the hip Acetabular retroversion (reverse PAO)

Thorough preoperative planning is essential to assess whether the desired position can be achieved. Increasingly 3D CT scans are used for preoperative planning. In addition, 3D printing has been used to understand the problem and plan surgical correction. Computer navigation and robotics are novel adjuncts that are aimed at obtaining an accurate correction of the concerned deformity.

DEGENERATIVE AND INFLAMMATORY DISORDERS OF THE HIP

Osteoarthritis

OA is referred to as primary when no predisposing cause can be found, and secondary when it develops after an insult to the hip joint. A multitude of factors, including genetic,

biochemical and mechanical influences, have been implicated in the development of primary OA. The exact mechanism for the development of primary OA remains unknown and it is therefore termed idiopathic. However, FAI has been proposed as an aetiological factor responsible for the development of OA by a Swiss group in 1999 (see *Further reading*). Secondary OA develops following trauma, AVN, dysplasia, slipped capital femoral epiphysis, inflammatory arthropathy or other known predisposing causes. The causes of OA of the hip are provided in *Table 39.5*.

TABLE 39.5 Aetiology of osteoarthritis.

Primary	• Cause unknown, termed idiopathic • Associations: for example, genetics, obesity
Secondary	• Trauma • Avascular necrosis • Inflammatory arthropathy (e.g. rheumatoid arthritis) • Perthes' disease • Developmental dysplasia of the hip • Slipped capital femoral epiphysis • Septic arthritis • Femoroacetabular impingement implicated as a possible cause

Clinical features

OA of the hip affects 10–25% of those aged 65 years or older. The most consistent symptoms are groin pain and limitation of movement. The pain may also radiate down to the knee joint; in some cases the only presenting feature may be a painful knee. In the early stages of the disease, pain is activity related but as the disease progresses the patient also complains of pain at rest. The patient frequently complains of night pain and may also find it difficult to get into a comfortable position while sleeping. Functionally, any activity that involves flexion and rotation is difficult to perform, e.g. putting on shoes and socks and getting into and out of a bath or a car. As the pain increases the hip joint gradually loses its movement because of muscle spasm, capsular contracture and osteophyte formation, leading to further limitation of activities.

Clinical examination may reveal gluteal muscle wasting. There may also be a limp, with a positive Trendelenburg's test. Leg length discrepancy, usually shortening, and limitation of movement, particularly internal rotation, are consistent features. Many patients present with a fixed flexion deformity that is best elicited by a modified Thomas's test (see *Chapter 35*).

Investigations

The characteristic features on a plain radiograph are (i) a reduction of the joint space, (ii) sclerosis in the subchondral bone, (iii) subchondral cysts, and (iv) osteophyte formation (*Figure 39.7*). Eventually, a collapsed femoral head may also be evident.

Management

There is no specific pharmacological therapy for OA; however, non-operative treatment with non-steroidal anti-inflammatories, regular exercise, physiotherapy and modification of lifestyle with loss of weight does help. Patients should also be encouraged to use walking aids (usually a walking stick in the opposite hand) to offload the affected hip joint and to reduce the workload of the ipsilateral abductors.

The indications for surgery are relentless pain (usually night pain), limitation of lifestyle and activities of daily living and failure of non-operative treatment. The surgical options include an arthrodesis (fusion), an osteotomy (realignment)

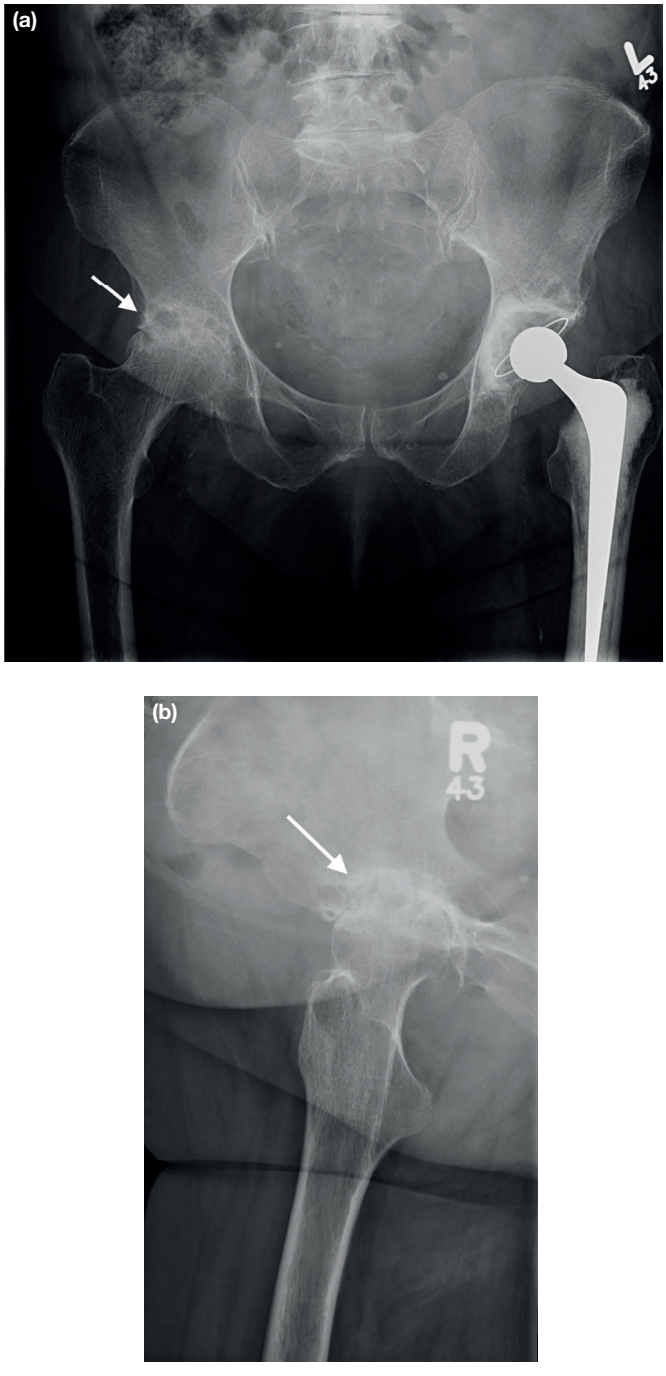

Figure 39.7 **(a)** Anteroposterior radiograph of the hip joint showing severe osteoarthritis of the right hip (arrow) and a cemented total hip replacement on the left; **(b)** lateral view of the right hip.

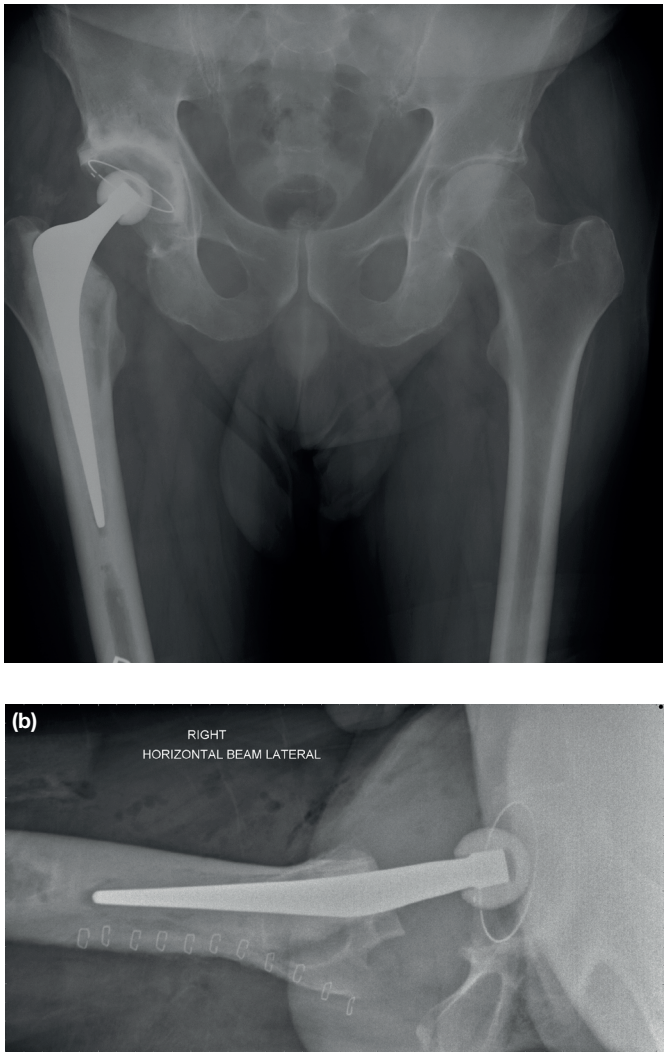

Figure 39.8 Radiographs showing a cemented total hip replacement *in situ*. **(a)** Anteroposterior view and **(b)** lateral view.

or a joint replacement (***Figures 39.7a, 39.8 and 39.9***). The indications are based on limitation of lifestyle and individual needs, thereby making it a truly life-improving and life-changing operation.

Summary box 39.4

OA of the hip

- OA is a degenerative condition leading to progressive damage of the articular cartilage and other joint structures
- The most consistent clinical features are groin pain and limitation of movement
- Characteristic radiological features are reduced joint space, subchondral sclerosis, subchondral cysts and osteophyte formation
- Non-operative treatment includes walking aids, non-steroidal analgesics, physiotherapy and weight loss
- Surgical options include osteotomy, arthrodesis or a joint replacement

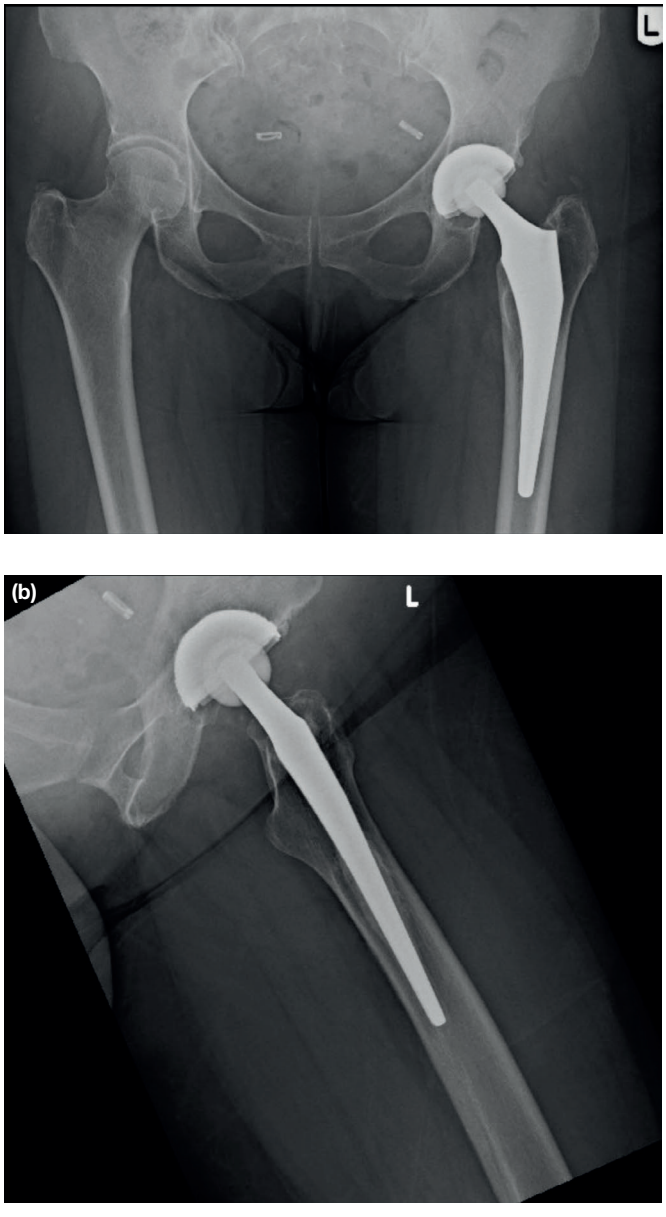

Figure 39.9 Radiographs of an uncemented total hip replacement. **(a)** Anteroposterior view and **(b)** lateral view.

Inflammatory arthritis

The hip joint can also be affected by inflammatory arthritides; however, these are not as common as OA. This group includes rheumatoid arthritis, ankylosing spondylitis, gout and chondrocalcinosis, juvenile rheumatoid arthritis and systemic lupus erythematosus.

SURGICAL PROCEDURES FOR DEGENERATIVE HIP CONDITIONS

Arthrodesis of the hip

Arthrodesis or fusion of the hip is an uncommon operation. It is generally reserved for young patients with severe OA who have

heavy manual jobs and in whom joint replacements are likely to fail early. The aim is to achieve a painless joint by fusing it in a functional position, which is about 30° of flexion, 15° of external rotation and 5° of abduction. This can be achieved by an intra-articular dynamic hip screw or by an extra-articular plate with screws.

Several problems can occur following an arthrodesis, including altered gait and excessive loading of the ipsilateral knee, the contralateral hip and the spine. Degenerative change in these joints in the long term is the rule rather than the exception.

Summary box 39.5

Features of an ideal joint replacement

- Biocompatible
- Well fixed to the host tissue, stable and allowing a good range of movement
- Bearing surfaces should be designed to minimise friction and have improved wear characteristics
- Material released from the bearings should be non-toxic
- Remove the minimum amount of bone
- Produce mechanical stability
- Should ideally outlive the patient

Primary total hip replacement

Over 95 000 primary THRs are performed annually in the UK (National Joint Registry, UK). The success rate for THR is very high and the evidence supports the results being more than encouraging. In the modern era, with evidence-based technique and selection of prosthesis, over 95% of patients will have a well-functioning THR at 10 years after surgery. In the best series, 85% will still be functioning at 20 years, although some are still in place because the patient may have increasing comorbidities, preventing revision of the THR. Following surgery, pain is reduced and there is improvement in mobility and sleep, as well as social and sexual function. Nevertheless, with the ever-increasing number of patients with joint replacements, the number of patients whose replacement has failed and come to the point of revision, or even re-revision, is rising.

Principles and design of hip replacements

Joint replacement should be biocompatible and made of inert materials. It should be well fixed to the host tissue and the design should incorporate features that allow a good range of movement and stability. The bearing surfaces should produce low friction and minimise the amount of wear particles produced which in turn prevents early loosening. The material released from the bearing surface should be non-toxic. The procedure should remove the minimum amount of the patient's bone so that revision is possible, and it should create a biomechanically stable joint. Finally, any implanted joint should ideally outlive the patient and be cost-effective.

Materials for the femoral component

Implants available currently are made of cobalt chrome alloy, stainless steel or titanium. Metal implants are able to withstand high loads, are relatively inert and can be manufactured easily. However, they do pose problems in terms of ion release if they are used as bearing surfaces. Also, corrosion can be a cause for concern if two dissimilar metals are used.

Bearing surfaces

The design described by Charnley in 1961 revolutionised THR and became a gold standard by using a bearing surface of metal on high-density polyethylene. This is described as a hard-on-soft bearing surface and has a low coefficient of friction, which in turn produces lower wear of the polyethylene component, resulting in longer survival of the prosthesis. Hence the phrase low-friction arthroplasty was given to this implant. High-density polyethylene has good shock-absorbing properties but does wear slowly over the years, producing small particles that can stimulate an inflammatory response in the joint, which then leads to osteolysis and aseptic loosening of the implants. The activated macrophages resorb bone and may also stimulate osteoclasts to do the same. There has therefore been a move towards using bearing surfaces with a lower wear rate, such as ceramic on ceramic. With metal-on-metal bearing surfaces, although the wear rate is lower, the wear particles are smaller (nano rather than micro) and can lead to an adverse reaction, particularly in the soft tissues, resulting in failure. There is increasing evidence that these implants are less forgiving than conventional metal-on-polyethylene THRs, appearing to require more precise implant positioning. Ceramic femoral head bearings on polyethylene cups are low friction, but ceramic femoral heads on ceramic acetabular cups have the lowest friction of all. However, ceramic-on-ceramic bearings are expensive to manufacture, and are another example of hard-on-hard bearings and produce small-sized wear particles. A summary of the advantages and disadvantages of each bearing surface is provided in ***Table 39.6***.

Fixation of implants

Artificial joints must be securely fixed to the bone on each side of the joint so that the implant does not work loose. This can be achieved with the help of cement or biological interdigitation between the prosthesis and bone (***Table 39.7***).

Traditionally, hip replacements were fixed into a bed of polymethylmethacrylate (PMMA) cement (***Figure 39.8***). The cement acts as a grout (spacer) and not as a glue between the implant and the bone. In the majority of cases, it gives an excellent outcome as shown by data in several national joint registries. However, it can cause potential problems: cement pressurisation can result in release of cement and marrow contents into the patient's blood stream. This can cause a drop in blood pressure. Improvements in cementing techniques allow for no gaps in the cement mantle between the femoral component and the bone. In spite of all the measures taken, occasionally there may be small areas in the cement mantle without cement.

Sir John Charnley, 1911–1982, Professor, Wrightington Hospital, UK, pioneer in hip replacement design, particularly the concept of low-friction arthroplasty.

TABLE 39.6 Bearing surfaces for hip replacements.

Type of bearing	Advantages	Disadvantages	Current use
Metal on polyethylene	Proven efficacy; easy to manufacture; cheap	Comparatively high friction; high wear rates; wear particles excite an inflammatory response that leads to osteolysis	Favourable in older age group >70 years
Ceramic on polyethylene	Lower wear rate	Expensive; ceramic fracture can be a problem	Preferrable in younger patients <70 years. Newer polyethylene – UHMWPE – has low wear rate
Metal on metal	Lower wear rate	Problem with metal ion release leading to adverse reaction to metal debris and severe osteolysis. Published examples of failure requiring early revision; implant recalls; expensive	Only a select group of patients – young male. Use head size larger than 48 mm
Ceramic on ceramic	Newer delta ceramics have the lowest wear rate	Very expensive; ceramic can fracture; squeaking	High-functioning young patients

UHMWPE, ultra-high-molecular-weight polyethylene.

TABLE 39.7 Fixation of implants.

Method of fixation	Component	Advantages	Disadvantages
Cemented	Femur	Implant does not need to fit cavity exactly; well-proven results	Cement polymerisation is exothermic with possibility of thermal injury; fragments may cause third-body wear and stimulate aseptic loosening; difficult to remove at revision
	Acetabulum	Cheap, can be used in osteoporotic bone	Higher shear forces leading to failure
Uncemented	Femur	No cement required; fixation more secure; dynamic and biological fixation	Risk of fracture; fit must be perfect; osseous integration may not be established; expensive
	Acetabulum	Good fixation into acetabulum; can be augmented with screws to secure fixation	Improper technique can lead to acetabular fracture

On the other hand, this problem can be obviated by using an uncemented prosthesis in which biological fixation can be achieved by providing a rough surface on the prosthesis for bone to grow into the porous surface of the prosthesis or by coating the surface of the prosthesis with hydroxyapatite, an osteoconductive agent, to encourage bone to bond to the prosthesis (*Figure 39.9*). These uncemented devices have also shown good long-term outcomes, although they can be associated with higher implant costs, increased risk of intraoperative fracture and difficulty in removing them if revision surgery is required in the future.

Surgical approaches to the hip, postoperative course and complications

The operation can be performed via a posterior approach, a trochanteric osteotomy, an anterolateral or Hardinge approach or an anterior approach (*Table 39.8*). Each approach has its own advantages and disadvantages. Minimally invasive surgery has been described that shortens the size of the incision and attempts to lessen soft-tissue damage. As access can be restricted, specialised instruments have been developed to facilitate this. Although the concept is attractive, no long-term benefits have been conclusively shown in minimally invasive hip surgery over the conventional technique. Eventually, whichever approach is used, it is essential to be able to implant a prosthesis so as to reproduce the patient's anatomy such that the implant has the correct offset, is at the correct centre of rotation with the correct component orientation, restores leg length and carries minimal risk of complications.

The postoperative course generally involves a 2- to 3-day stay in hospital but day case hip replacements are being performed in a select group of patients in some centres. The physiotherapist encourages the patient to mobilise safely and independently, avoiding any movements that might lead to a dislocation (*Figure 39.10*). Postoperative plain radiographs are essential to ensure that implants are in correct alignment and orientation, and rule out any iatrogenic fracture. Prior to discharge, the occupational therapist assesses the patient's home circumstances and arranges for any modifications that may be

Kevin Hardinge, b. 1939, orthopaedic surgeon, Wrightington Hospital, UK, described the direct lateral approach to the hip in 1982.

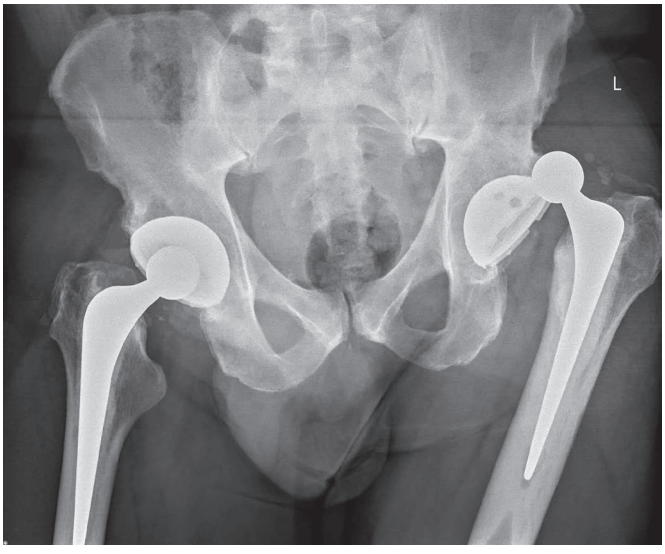

Figure 39.10 Anteroposterior radiograph showing dislocation of a left hybrid total hip replacement (cemented femoral stem and uncemented acetabular component).

required to assist the patient, e.g. a raised toilet seat. For the first 6 weeks patients are advised to avoid movements that make the THR prone to dislocation. Outpatient follow-up visits are arranged at 6 weeks and at 1 year post surgery. Although THR is generally a successful and safe procedure, it does have associated complications. A comprehensive list of complications is provided in *Table 39.9*. Perioperative administration of antibiotics is a very important part in prevention of infection in addition to adequate aseptic precautions in the operating theatre. Venous thromboembolism is a risk following THR and deep vein thrombosis (DVT) is relatively common if no precautions are taken to reduce this risk. DVT can lead to pulmonary embolism (PE), which can be fatal. Hence steps need to be taken to minimise the risk for both DVT and PE, including adequate hydration, the use of regional anaesthesia and early postoperative mobilisation. In addition, both mechanical device (thromboembolic deterrent [TED] stockings, foot pumps or intermittent pneumatic calf compression devices) and chemical thromboprophylaxis (low-molecular-weight heparin, warfarin or oral anticoagulants) are commonly prescribed for a period of 4–6 weeks after surgery to reduce the risk of DVT (this depends on local and national guidelines).

TABLE 39.8 Surgical approaches to the hip.

Surgical approach	Anatomical interval and muscle
Posterior	Along the fibres of the gluteus maximus, and dividing the short external rotators
Trochanteric	A trochanteric osteotomy is required
Anterolateral/ Hardinge	Parts of the gluteus medius and minimus are reflected off the greater trochanter
Anterior	The interval is developed between the sartorius and tensor fascia lata superficially and rectus femoris and gluteus medius deeply

TABLE 39.9 Complications of total hip replacement.

Intraoperative complications	• Nerve injury – sciatic, femoral and obturator nerves • Vascular injury – femoral vein and artery • Femoral or acetabular fracture • Fragments of cement left in joint
Postoperative complications	• Infection • Deep vein thrombosis and pulmonary embolism • Leg length inequality • Dislocation • Heterotopic ossification • Septic/aseptic loosening • Implant breakage/failure

Revision total hip replacement

Revision of a THR is required if the patient is symptomatic secondary to failure of the implant by loosening (*Figure 39.11*), recurrent dislocations or a periprosthetic fracture. Rarely the femoral prosthesis itself can fracture, leading to pain and disability requiring revision surgery. Loosening of the implant can occur as a result of an infection or aseptic loosening. Aseptic osteolysis is caused by an inflammatory response secondary to particle wear, which can be from either polyethylene or metal.

In the initial stages of loosening the patient complains of pain, which is experienced mainly on weight-bearing. Thorough assessment to rule out infection is essential to plan further treatment. A history of infection (can also be reported as problems with wound healing) in the immediate postoperative period may suggest infection as a cause of premature implant loosening. The infection can be low grade, with *Staphylococcus*

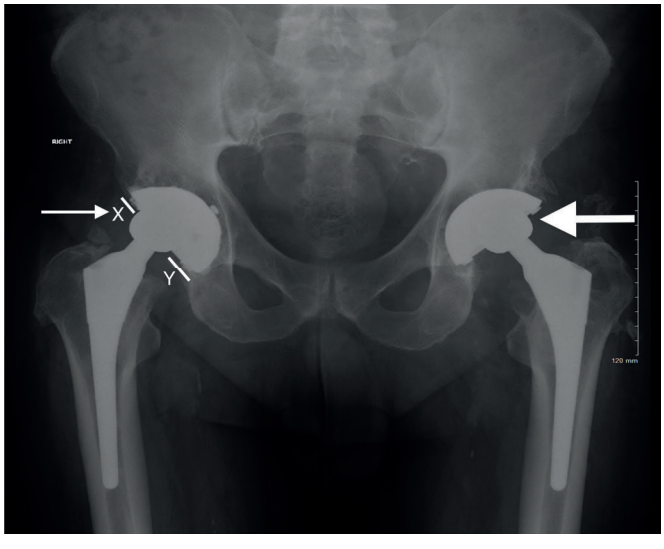

Figure 39.11 Significant acetabular wear, eccentric position of the femoral head (arrow indicating left side wear) and osteolysis behind the acetabular component. Right hip wear is also seen (thin arrow). Distance X should be equal to distance Y. Here, distance X is considerably smaller than distance Y, indicating eccentric wear of the polyethylene (thin arrow).

epidermidis multiplying slowly within a glycocalyx coating, and therefore normal measures of infection such as a raised C-reactive protein (CRP) may be equivocal (see ***Chapter 43***). The Musculoskeletal Infection Society (MSIS) has defined several criteria (major and minor) to help with the diagnosis of prosthetic joint infection. The diagnosis of infection is aided by an elevated CRP and erythrocyte sedimentation rate; a joint aspirate or biopsy is also useful to identify a pathogen. In addition, a labelled white cell scan and single photon emission CT (SPECT) can provide additional information.

Revision THR can be a single-stage or a two-stage procedure depending on the indication. If the loosening is secondary to infection, a two-stage revision is usually preferred. The first stage consists of implant removal, thorough debridement and implantation of an antibiotic-loaded cement spacer. Multiple deep specimens are sent for bacteriology to determine the organism and its antimicrobial sensitivity. The patient is subsequently prescribed an appropriate antibiotic regime (see ***Chapter 43***). At the second stage of the procedure, the cement spacer is removed and a new prosthesis implanted. In the case of aseptic loosening, revision is performed as a single-stage procedure. If there has been a significant amount of bone loss, bone grafting or trabecular metal augments may be required. The results following a revision hip replacement are not as good as those following a primary THR and the rate of complications, especially dislocation, is also higher. Specialised acetabular components such as dual-mobility implants are favoured in a revision setting, especially for recurrent dislocation in those with poor muscle function.

FURTHER READING

Ben-Shlomo Y, Blom A, Boulton C *et al. The National Joint Registry 18th annual report 2021*. London: National Joint Registry; 2021. Available from https://www.ncbi.nlm.nih.gov/books/NBK576858/

Bulstrode C, Wilson-MacDonald J, Eastwood DM *et al. Oxford textbook of trauma and orthopaedics*, 2nd edn. Oxford: Oxford University Press, 2017.

Ganz R, Parvizi J, Beck M *et al.* Femoroacetabular impingement: a cause for osteoarthritis of the hip. *Clin Orthop*. 2003; **417**: 112–20.

Houcke JV, Khanduja V, Pattyn C, Audenaert E. The history of biomechanics in total hip arthroplasty. *Indian J Orthop* 2017; **51**(4): 359–67. Erratum in: *Indian J Orthop* 2017; **51**(5): 629.

Khanduja V, Villar RN. Arthroscopic surgery of the hip: current concepts and recent advances. *J Bone Joint Surg Br* 2006; **88**(12): 1557–66.

Magrill ACL, Nakano N, Khanduja V. Historical review of arthroscopic surgery of the hip. *Int Orthop* 2017; **41**(10): 1983–94.

Matsumoto K, Ganz R, Khanduja V. The history of femoroacetabular impingement. *Bone Joint Res* 2020; **9**(9): 572–7.

Miller M, Thompson SR. *Miller's review of orthopaedics*, 8th edn. Philadelphia: Elsevier, 2019.

Nakano N, Yip G, Khanduja V. Current concepts in the diagnosis and management of extra-articular hip impingement syndromes. *Int Orthop* 2017; **41**(7): 1321–8.

Palmer AJR, Ayyar Gupta V, Fernquest S *et al.* FAIT Study Group. Arthroscopic hip surgery compared with physiotherapy and activity modification for the treatment of symptomatic femoroacetabular impingement: multicentre randomised controlled trial. *BMJ* 2019; **364**: l185. Erratum in: *BMJ* 2021; **372**: m3715.

Parvizi J, Tan TL, Goswami K *et al.* The 2018 definition of periprosthetic hip and knee infection: an evidence-based and validated criteria. *J Arthroplasty* 2018; **33**(5): 1309–14.e2.

Sunil Kumar KH, Rawal J, Nakano N *et al.* Pathogenesis and contemporary diagnoses for lateral hip pain: a scoping review. *Knee Surg Sports Traumatol Arthrosc* 2021; **29**(8): 2408–16.

Warwick D, Blom A, Whitehouse M. *Apley and Solomon's concise system of orthopaedics and trauma*, 5th edn. Abingdon: CRC Press, 2022.